

## Interferonopathies (and how they may relate to COVID-19)

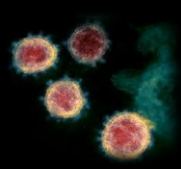
**2<sup>nd</sup> MDS/SDH Joint COVID-19 Minisymposium**  
**May 19, 2020**

Edward W. Cowen, MD, MHSc  
Senior Clinician and Head, Dermatology Consultation Service  
National Institute of Arthritis and Musculoskeletal and Skin Diseases

Adjunct Professor, Department of Dermatology  
Uniformed Services University of the Health Sciences

Professor, Department of Dermatology  
Georgetown University School of Medicine

**NIH** National Institutes of Health  
Turning Discovery Into Health



1

## Speaker Disclosure

Views expressed are my own and do not represent  
the official position of the NIH or the US Government

2


## Skin manifestations associated with COVID-19

PCR pos.

↑

PCR neg.


- Poor prognosis
  - Retiform purpura
  - Acral ischemia
- ? Prognosis
  - Morbilliform
  - Urticarial
  - Vesicular
  - Transient livedo
- Good prognosis
  - Perniosis-like



N Engl J Med 2020; 100: 100-101  
Acta Derm Venereol 2020; 100: 100-101

3

## Perniosis-like manifestations of COVID-19



Cordero KM, Reynolds SD, Wattler R, McCalmont TH. *Pediatr Dermatol*. 2020 May 12. [Epub ahead of print]

4

## Perniosis-like manifestations of Aicardi-Goutières S.



2 yo girl, homozygous missense mutation in SAMHD1. Courtesy Julie Schaffer, MD

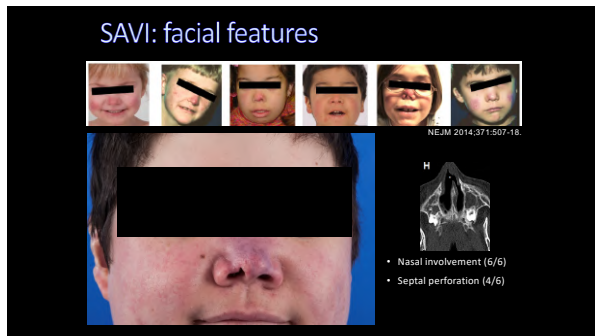
5

## Questions

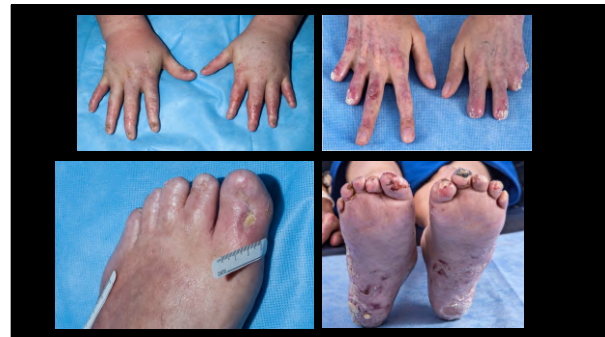- Do COVID-19 skin manifestations share similar pathogenesis to those seen in interferonopathies?
- What do skin findings tell us regarding the ab/normal immune response in COVID-19?
- Can these genetic diseases offer insight into potential therapy?

6

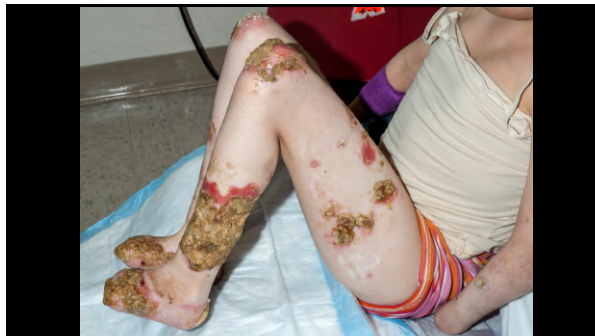



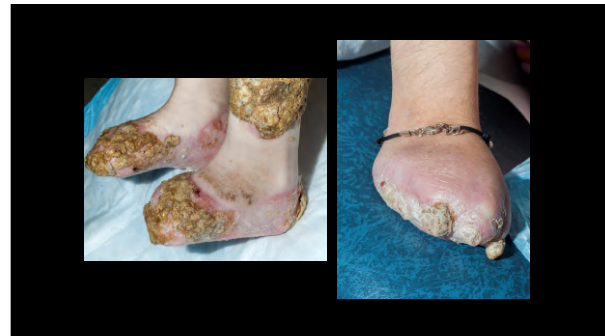13



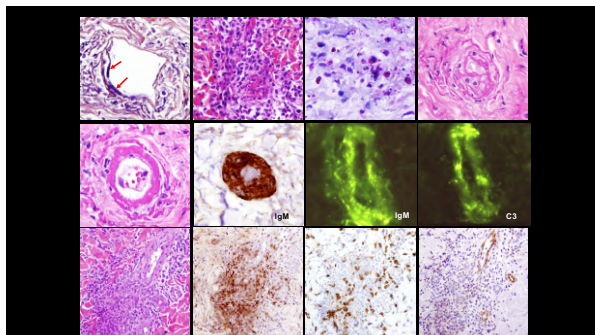
14



15



16



17

SAVI: Prognosis

- High mortality (3/7)
- Unresponsive to multiple agents
  - Pred, CYP, AZA, CSA, MTX, MMF, IVIG, belimumab, HCO, anti-TNF, leflunomide, RTX, ASA, nifedipine

*Clinical Images: Stimulator of interferon genes-associated vasculitis of infancy*

Arthritis Rheumatol 2015 Mar;67(3):808.


18

**Chronic Atypical Neutrophilic Dermatitis with Lipodystrophy and Elevated temperature syndrome**

- Perinatal
  - Fever, persistent erythematous, annular plaques
- Late infancy
  - Periorbital erythema, digital edema
- Early childhood
  - Lipodystrophy, LAD, anemia, arthritis/arthralgia
- Late childhood
  - Hepatomegaly, cardiomyopathy, contractures

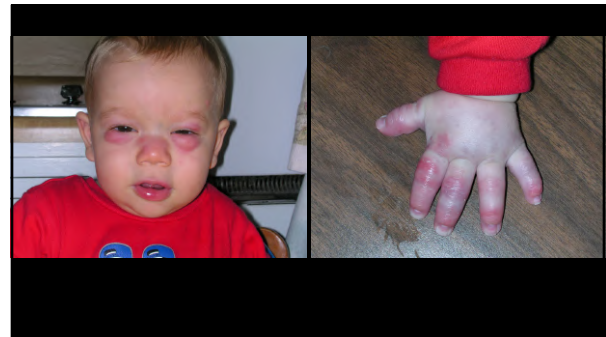LABS:  
Elevated ESR/CRP  
Elevated Interleukin-6 → Tocilizumab  
Improved fever  
No change skin lesions

[Erol Duzgun, 2016 May;175\(5\):735-40.](#)

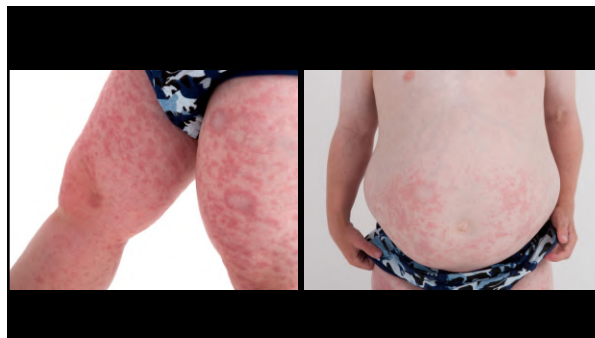

J Am Acad Dermatol 2010;62:489-95. Arthritis Rheum 2012; 64:895-907.

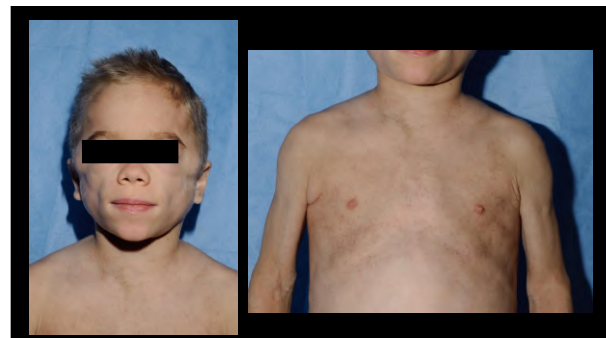19



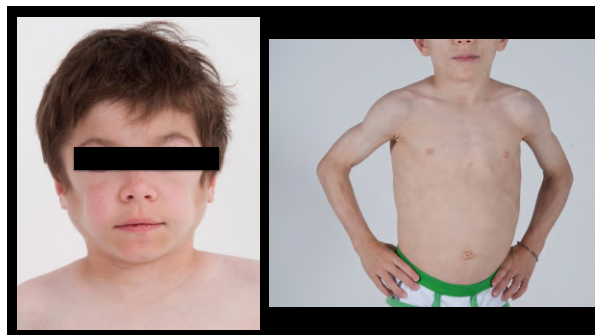20



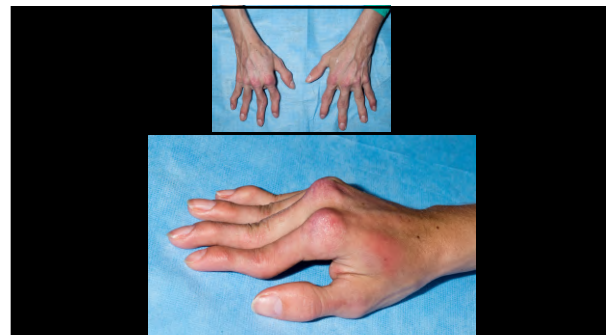21



22



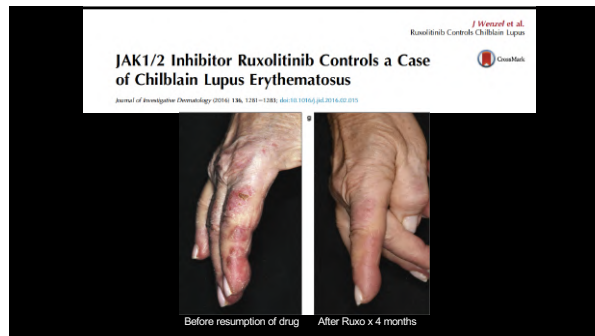23



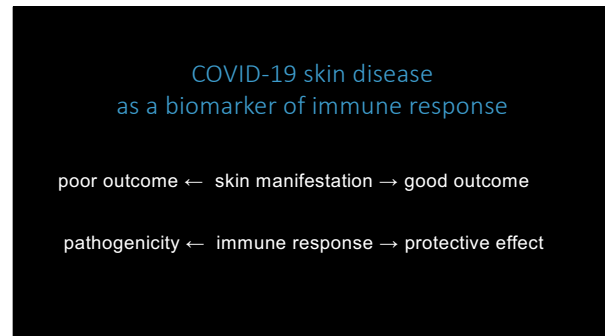
24



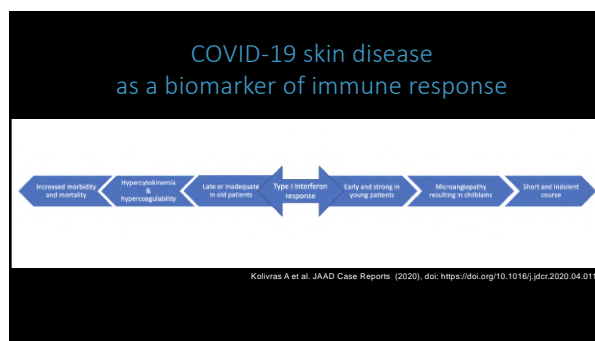





31



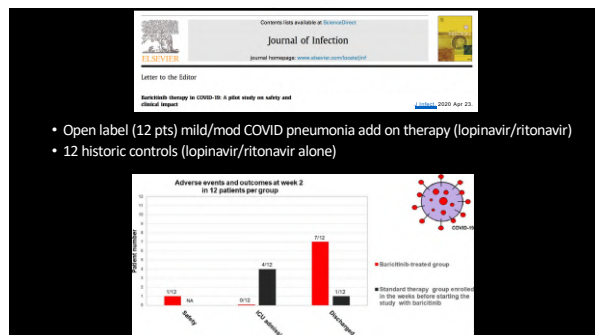
32



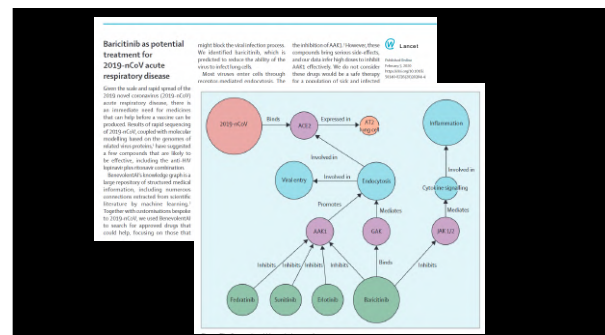
33



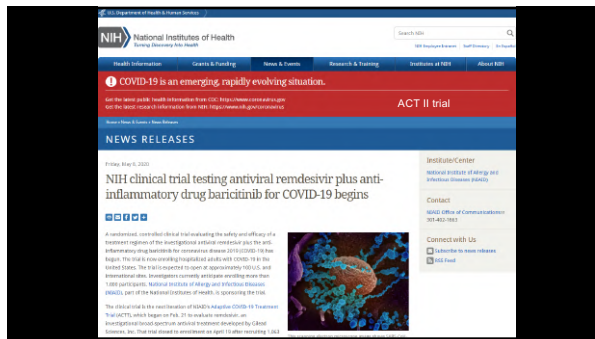
34



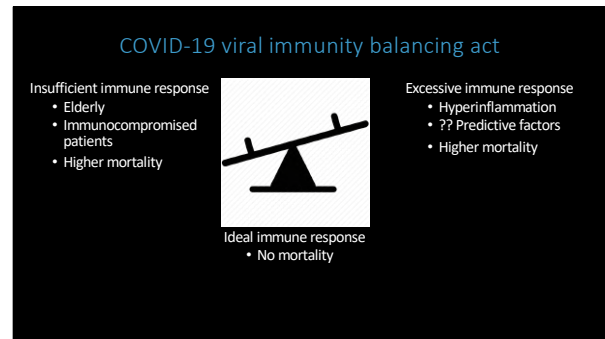
35



36



37



38